

*Jerrold H. Levy, M.D., F.A.H.A., F.C.C.M., Editor*

## Ultrasound for “Lung Monitoring” of Ventilated Patients

Belaïd Bouhemad, M.D., Ph.D., Silvia Mongodi, M.D., Gabriele Via, M.D., Isabelle Rouquette, M.D.

**I**N critically ill patients, bedside visualization of lung morphology and aeration loss is crucial to optimize positive end-expiratory pressure (PEEP) and other therapeutic procedures.<sup>1</sup> Although chest radiography is routinely performed, it has limited diagnostic performance, and lung computed tomography (CT) remains the reference method. Ultrasonography can be used at the bedside and gained widespread acceptance even in unexpected situations such as tracheal intubation<sup>2</sup> or evaluation of intracranial pressure.<sup>3</sup> Lung ultrasonographic (LUS) examination allows rapid and reliable diagnosis of lung consolidation, pleural effusion, or interstitial–alveolar syndrome.<sup>4</sup> Assessment of patients at intensive care unit admittance with LUS combined with general ultrasound protocol provides rapidly and easily accurate information with diagnostic and therapeutic relevance.<sup>5–7</sup> Therefore, LUS is now included in a consensus statement on core competencies in point-of-critical-care ultrasound.<sup>8</sup>

The aim of this Clinical Concept and Commentary is to review how LUS can be used by physicians at the bedside to manage hypoxemic ventilated patients for setting mechanical ventilation parameters and monitoring the effects of any therapy aimed at improving lung aeration.

### Lung Ultrasound Findings

#### Lung Ultrasound Examination

It must be performed according to a systematic protocol of examination.<sup>9</sup> LUS is normally performed in supine patients. Operator should firstly locate the diaphragm and the lungs. Lung consolidation or pleural effusion is found predominantly in dependent and dorsal lung regions and

can be easily distinguished from liver or spleen once the diaphragm has been identified. By using the anterior and posterior axillary lines as anatomical landmarks, three areas per hemithorax (anterior, lateral, and posterior) can be identified. Each area is divided in two, superior and inferior. In a given region of interest, lung surface of all adjacent intercostal spaces must be explored by moving the probe transversally.<sup>9</sup> Posterior areas can be more extensively examined (until the spine) if a slight patient rotation on the contralateral side is performed; posterior superior area is sometimes difficult to evaluate because the scapula can determine a blind spot (fig. 1).

Different probes can be suitable for LUS; the choice of the more suitable one depends on the patient size and the suspected pathology. Linear probes have high superficial definition and low penetration capacity due to their high frequency; they are therefore suitable in thin parietal wall patients, mainly in anterior fields, and in pleural pathologies evaluation (*i.e.*, pneumothorax). Phased-array and convex probes are more suitable to deep pathologies examination (consolidations and pleural effusions) and for thick parietal wall areas, mainly lateral and posterior. Microconvex probes are more flexible and can be suitable for both superficial and deep pathology evaluation due to their wide frequency range.

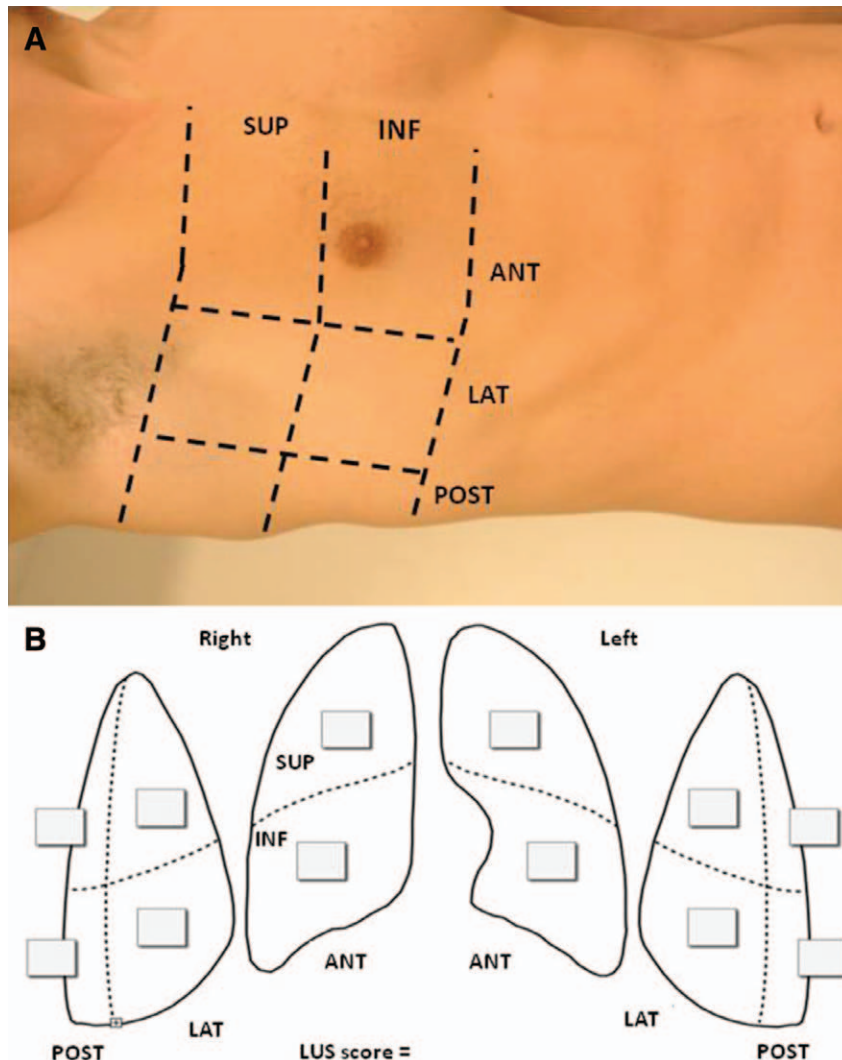
#### Normal Findings

Ultrasonounds are not transmitted through normally aerated lung, and only the pleural line can be seen. It appears as a hyperechoic and sliding line, moving forward and backward with ventilation, resulting from the movement of

Supplemental Digital Content is available for this article. Direct URL citations appear in the printed text and are available in both the HTML and PDF versions of this article. Links to the digital files are provided in the HTML text of this article on the Journal's Web site ([www.anesthesiology.org](http://www.anesthesiology.org)). Figure 7 was prepared by Annemarie B. Johnson, C.M.I., Medical Illustrator, Vivo Visuals, Winston-Salem, North Carolina.

Submitted for publication August 5, 2013. Accepted for publication September 3, 2014. From the Department of Anesthesiology and Intensive Care, C.H.U. Dijon, Dijon Cedex, France (B.B.); 1st Department of Anesthesia and Intensive Care, Istituto di Ricovero e Cura a Carattere Scientifico, Policlinico San Matteo Foundation, Pavia, Italy (S.M., G.V.); and Department of Anesthesiology, Groupe Hospitalier Paris-Saint-Joseph, Paris, France (I.R.).

Copyright © 2014, the American Society of Anesthesiologists, Inc. Lippincott Williams & Wilkins. Anesthesiology 2015; 122:00–00



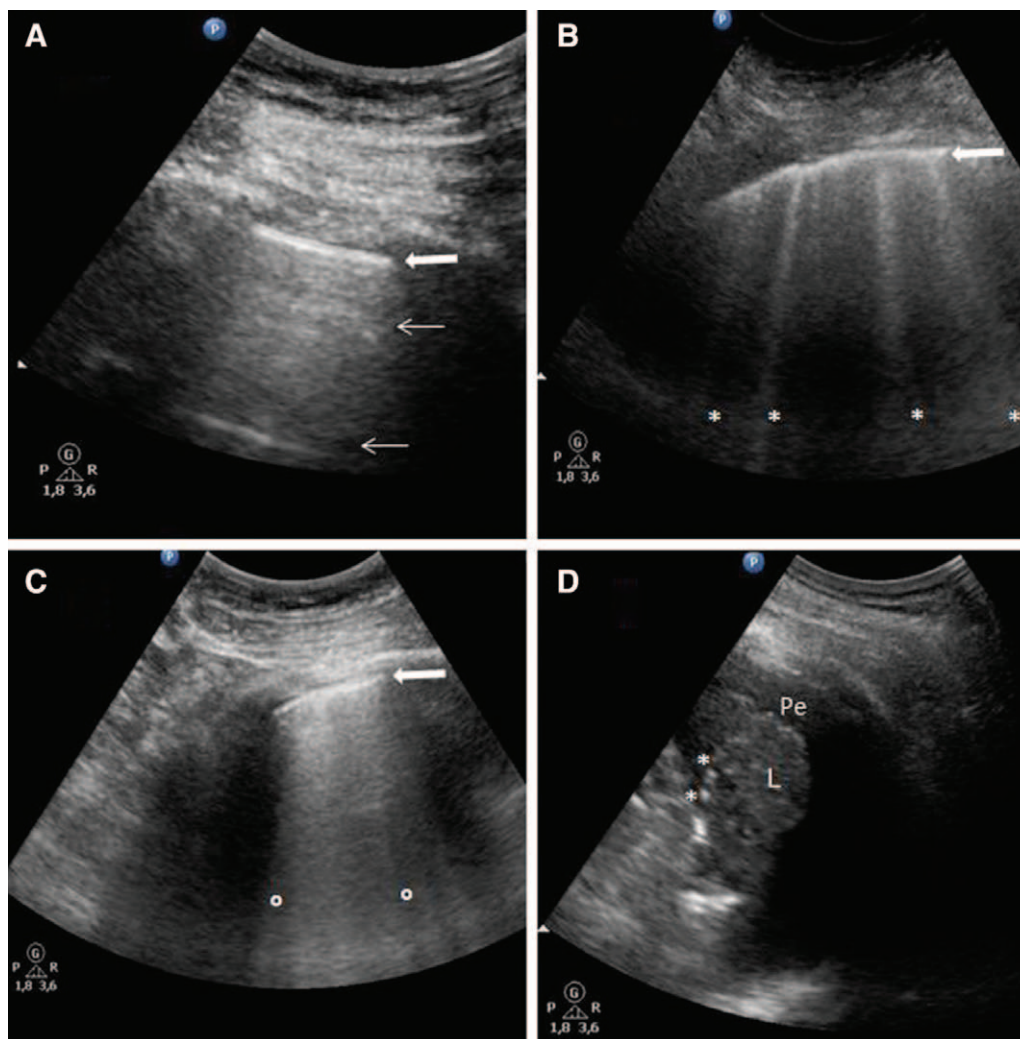
**Fig. 1.** Lung ultrasound examination and report. (A) Each hemithorax is systematically divided in six regions: two anterior, two lateral, and two posterior, according to anatomical landmarks set by anterior and posterior axillary lines. Each region is divided in half, superior, and inferior. To perform a comprehensive examination, all adjacent intercostal spaces must be explored in each region of interest, sliding the probe along the space. (B) Examples of simplified report form for rapid reporting and monitoring. For each explored region, the worst finding is reported in simple *checkboxes* according to the following rating: normal: 0; well-separated B-lines: 1; coalescent B-lines: 2; and consolidation: 3. The cumulative lung ultrasound (LUS) score corresponds to the sum of each examined region score (minimum score, normal lungs: 0; maximum score, both consolidated lungs: 36). ANT = anterior; INF = inferior; LAT = lateral; POST = posterior; SUP = superior.

the visceral pleura against the parietal pleura during the respiratory cycle. Beyond this pleural line, motionless and regularly spaced horizontal lines to the pleura, A-lines, are visualized; they correspond to normal reverberation artifact of the pleural line. A-lines and lung sliding define normal aeration (fig. 2; see Supplemental Digital Content 1, <http://links.lww.com/ALN/B117>, video of normal pattern, where the pleural line can be seen with multiple horizontal A-lines).

### B-lines

Pulmonary edema results from increased capillary permeability (a hallmark of acute lung injury) or increased

intravascular hydrostatic pressure. This increase in extravascular lung water (EVLW) extends to lung periphery and produces vertical ultrasound artifacts resulting from the abnormal gas-tissue interface. They appear as shining vertical B-lines to the pleura line and arising from it reaching the edge of the screen erasing A-lines (fig. 2). They represent a reverberation artifact through edematous interlobular septa or alveoli.<sup>9,10</sup> (See Supplemental Digital Content 2, <http://links.lww.com/ALN/B118>, which is a video of moderate aeration loss pattern. The pleural line is visible with separated B-lines arising from the pleural line and spreading up to the edge of the screen. This pattern corresponds to moderate lung aeration loss resulting from interstitial syndrome.



**Fig. 2.** Lung ultrasound patterns corresponding to progressive loss of aeration. (A) Normal pattern. The pleural line (*white arrow*) can be seen with multiple horizontal A-lines (*thin arrows*). (B) The pleural line is visible (*white arrow*) with separated B-lines (\*) arising from the pleural line and spreading up to the edge of the screen. This pattern corresponds to moderate lung aeration loss resulting from interstitial syndrome. (C) The pleural line is visible (*white arrow*) with coalescent B-lines (between °) arising from the pleural line and spreading up to the edge of the screen. This pattern corresponds to severe lung aeration loss resulting from partial filling of alveolar spaces by pulmonary edema. (D) Transversal view of a consolidated lower lobe. Lung has a tissue-like echotexture (L). Hyperchoic images (\*) can be seen within the consolidation corresponding to dynamic air bronchograms (air-filled bronchi). Pe = pleural effusion.

See Supplemental Digital Content 3, <http://links.lww.com/ALN/B119>, which is a video of severe aeration loss pattern. The pleural line is visible with coalescent B-lines arising from the pleural line and spreading up to the edge of the screen. This pattern corresponds to severe lung aeration loss resulting from partial filling of alveolar spaces by pulmonary edema.)

### Lung Consolidation

Lung consolidation results from massive aeration loss such as in lobar bronchopneumonia, pulmonary contusion, and lobar atelectasis. It appears as a tissue-like echotexture (“hepatization”). Lung consolidation has a superficial boundary at the level of the pleural line or a pleural effusion if present and a

deep boundary usually irregular with the aerated lung or regular in case of whole lobe involvement. Within the consolidation, hyperchoic punctiform images can be seen, corresponding to air bronchograms (air-filled bronchi; fig. 2). Penetration of gas into the bronchial tree of the consolidation during inspiration produces an inspiratory reinforcement of these hyperchoic punctiform images (dynamic bronchograms).<sup>11</sup> (See Supplemental Digital Content 4, <http://links.lww.com/ALN/B120>, which is a video of transversal view of a consolidated lower lobe. Lung has a tissue-like echotexture. Hyperchoic tubular images can be seen within the consolidation. An inspiratory reinforcement corresponding to penetration of air into the bronchial tree can be seen. These hyperchoic images correspond to dynamic air bronchograms [air-filled bronchi].)

## Lung Ultrasound for Evaluation of Lung Aeration

To allow serial comparisons and monitoring, LUS requires an organized team effort with standardized reports of comprehensive examination. This cannot be achieved by brief written report including the capture of representative images either as video clips or as printed single images (difficult to store and to recall). First, one can report LUS examination of each explored region using simplified LUS pattern to obtain comprehensive picture of the lungs. Second, these patterns can be used to express aeration and its variation as a score.

### Lung Ultrasound Patterns Corresponding to Different Degrees of Aeration

Because LUS horizontal and vertical artifacts (A-lines and B-lines) are determined by the level of aeration, lung reaeration may be assessed by tracking LUS changes. To simplify, four LUS patterns (fig. 2), corresponding to increasing loss of aeration, can be used to monitor lung aeration semiquantitatively<sup>12</sup>: (1) presence of horizontal artifacts A-lines beyond the pleural line characterizes normal pulmonary aeration; (2) presence of multiple and well-separated vertical B-lines corresponds to moderate decrease in lung aeration resulting from interstitial syndrome; (3) presence of coalescent B-lines corresponds to more severe decrease in lung aeration resulting from partial filling of alveolar spaces by pulmonary edema or confluent bronchopneumonia; and (4) presence of lung consolidation corresponds to complete loss of aeration with persisting aeration of distal bronchioles (dynamic bronchograms).

### Lung Ultrasound Scores for Monitoring of Aeration

An LUS score of aeration can be calculated as follows: for each given region of interest, points are allocated according to the worst ultrasound pattern observed: normal = 0, well-separated B-lines = 1, coalescent B-lines = 2, and consolidation = 3. An LUS score ranging between 0 and 36 was calculated as the sum of each region.<sup>13</sup> This score is a global picture of lung aeration and can be regularly monitored. An increase in score indicates a decrease in aeration.

An LUS score of reaeration can also be calculated. This score is based on changes during an observational period of the ultrasound pattern of each region of interest. First, ultrasound lung aeration is estimated using LUS pattern at the beginning and the end of the period. This period could correspond to PEEP trial, prone position, or any therapy aimed at aeration improvement. In a second step, a score is given according to LUS pattern change observed in each region of interest (see score of aeration, Supplemental Digital Content 5, <http://links.lww.com/ALN/B121>). For example, change from consolidation to normal: 5 points; and from coalescent to well-separated B-lines: 1 point. A global LUS score of lung reaeration is calculated as the sum of each region score<sup>12,14</sup> (see an example of calculation of score of aeration during PEEP trial, Supplemental Digital Content 6, <http://links.lww.com/ALN/B122>).

Score of reaeration is accurate for determining changes in lung aeration in different clinical contexts.<sup>12,14</sup> An increase in score indicates an increase in aeration.

### Lung Ultrasound to Assess Distribution of Aeration Loss in Hypoxemic Patients

Tidal volume and PEEP required for lung-protective ventilation should be individualized and remain a challenge. In acute respiratory distress syndrome (ARDS) patients with heterogeneous distribution of aeration loss, applying too high pressures and volumes can lead to overinflation of aerated parts of the lung and promote ventilator-induced lung injury.<sup>1</sup>

In a majority of patients, aeration loss predominates in dependent lung regions (focal ARDS), and parts of upper lobes remaining normally aerated<sup>1</sup> are at risk of hyperinflation when intrathoracic pressures increase (PEEP, sighs, or recruitment maneuvers). Heterogeneous distribution of aeration is easily evidenced by LUS: normal pattern in upper anterior and lateral lung regions and consolidation or B-lines in lower posterior and lateral ones (dependent lung regions in supine position). Ventilation settings should be the result of a compromise between alveolar recruitment and lung hyperinflation.

In a minority of patients where aeration loss involves all lung regions homogeneously (diffuse ARDS), high PEEP can be tested<sup>1</sup>: the increase in intrathoracic pressure predominantly induces lung recruitment without significant hyperinflation. At a PEEP of 5 cm H<sub>2</sub>O or less, transthoracic LUS shows coalescent B-lines and/or consolidation in all intercostal spaces of anterior, lateral, and posterior pulmonary regions. Increases in PEEP change LUS patterns in recruited lung regions.<sup>12</sup>

### Lung Ultrasound to Quantify Lung Aeration Changes in ARDS Patients

Consolidations associated to B-lines are characteristic ultrasound patterns observed in patients with ARDS.<sup>9</sup> Ultrasound assessment of lung recruitment was first performed by measuring the decrease in the area of consolidated left or right lower lobes using either transesophageal echocardiography<sup>15–17</sup> or transthoracic LUS<sup>18</sup> in cardiac<sup>15</sup> and ARDS patients.<sup>16,17</sup> Although these studies were limited to nonaerated dependent regions, significant correlations were found between decrease in consolidated areas and improvement of oxygenation.

Confirming CT scan data obtained in ARDS patients,<sup>19,20</sup> LUS reveals the heterogeneous distribution of consolidations and pulmonary edema with the presence of spared areas.<sup>21</sup> Consolidated lung areas predominate in dependent lung regions and coexist with interstitial–alveolar edema present in anterior and lateral lung regions. To accurately quantify PEEP-induced lung recruitment, the whole lungs should be examined and reaeration of consolidations as well



as interstitial–alveolar edema should be taken into consideration. Score of reaeration based on the worst ultrasound pattern in 12 regions of interest (figs. 1 and 2) is accurate for determining treatment-induced changes in lung aeration.<sup>12,14</sup> In ARDS patients, LUS reaeration score not only estimates adequately PEEP-induced lung recruitment but also allows regional analysis of recruitment mechanisms. Recruitment mainly results from reaeration of poorly aerated lung regions rather than from reaeration of consolidations: coalescent B-lines are transformed into separated B-lines or A-lines, and separated B-lines are transformed into A-lines. Recruitment of consolidations is rarely observed (fig. 3).<sup>12</sup>

A practical approach based on LUS can be proposed to titrate PEEP in ARDS patients (fig. 4). The first step consists in evaluation of lung morphology at a PEEP 5 cm H<sub>2</sub>O or less. This can be done by examination of anterior areas of chest wall: presence of normal patterns in anterior areas of chest wall characterizes focal aeration loss; on the contrary in diffuse loss of aeration, well-separated or coalescent B-lines are found in all anterior areas of chest wall.

The second step consists in PEEP trial and monitoring of B-lines in anterior zones. For patient with focal loss of aeration, low level of PEEP ( $\leq 10$  cm H<sub>2</sub>O) can be tested. Higher levels rarely result in recruitment of consolidations<sup>12</sup> but expose to overdistension of normally aerated zones. This overdistension cannot be detected by LUS. For patient with diffuse loss of aeration, higher level of PEEP (12 to 14 to 16 cm H<sub>2</sub>O) can be tested. At each increase in PEEP, responsiveness can be monitored by LUS examination of anterior zones. PEEP can be increased by 3 to 4 cm H<sub>2</sub>O until anterior zones with moderate or severe aeration loss (respectively separated and coalescent B-lines) become normal (A-lines). Increasing PEEP further to obtain a complete disappearance of B-lines (in lateral zones) or consolidation (in posterior zones) theoretically exposes to overdistension of previously recruited anterior zones. The same reasoning can be done during decremental PEEP trials.

### **Lung Ultrasound to Quantify Extension and Resolution of Pulmonary Edema**

Cardiogenic pulmonary edema results from increased intravascular hydrostatic pressure. As a consequence, the distribution of alveolar flooding is homogeneous. An LUS pattern of cardiogenic pulmonary edema is characterized by the presence of multiple B-lines in all examined regions. On the contrary, ARDS is characterized by its heterogeneous pattern (fig. 5). Regions with multiple B-lines are associated with regions with A-lines (spared areas) or lung consolidations. This can be used to differentiate cardiogenic pulmonary edema from ARDS.<sup>22</sup>

Moreover homogeneous distribution of alveolar flooding allows evaluation of the amount of edema on score based on eight regions of interest limited to anterior and lateral chest walls. The simple sum of B-lines found in these regions yields a score correlated to the extent of extravascular lung

water; that is, the number of B-lines increases with the amount of EVLW. Such scores based on B-lines number were correlated to surrogate markers of pulmonary edema as EVLW measured by pulse indicator continuous cardiac output system or pulmonary wedge pressure.<sup>23–25</sup> Variation of EVLW during hemodialysis<sup>26</sup> or stress test<sup>24</sup> is also correlated to variations of numbers of B-lines. B-lines assessment to evaluate pulmonary edema during heart failure is now recommended.<sup>27</sup>

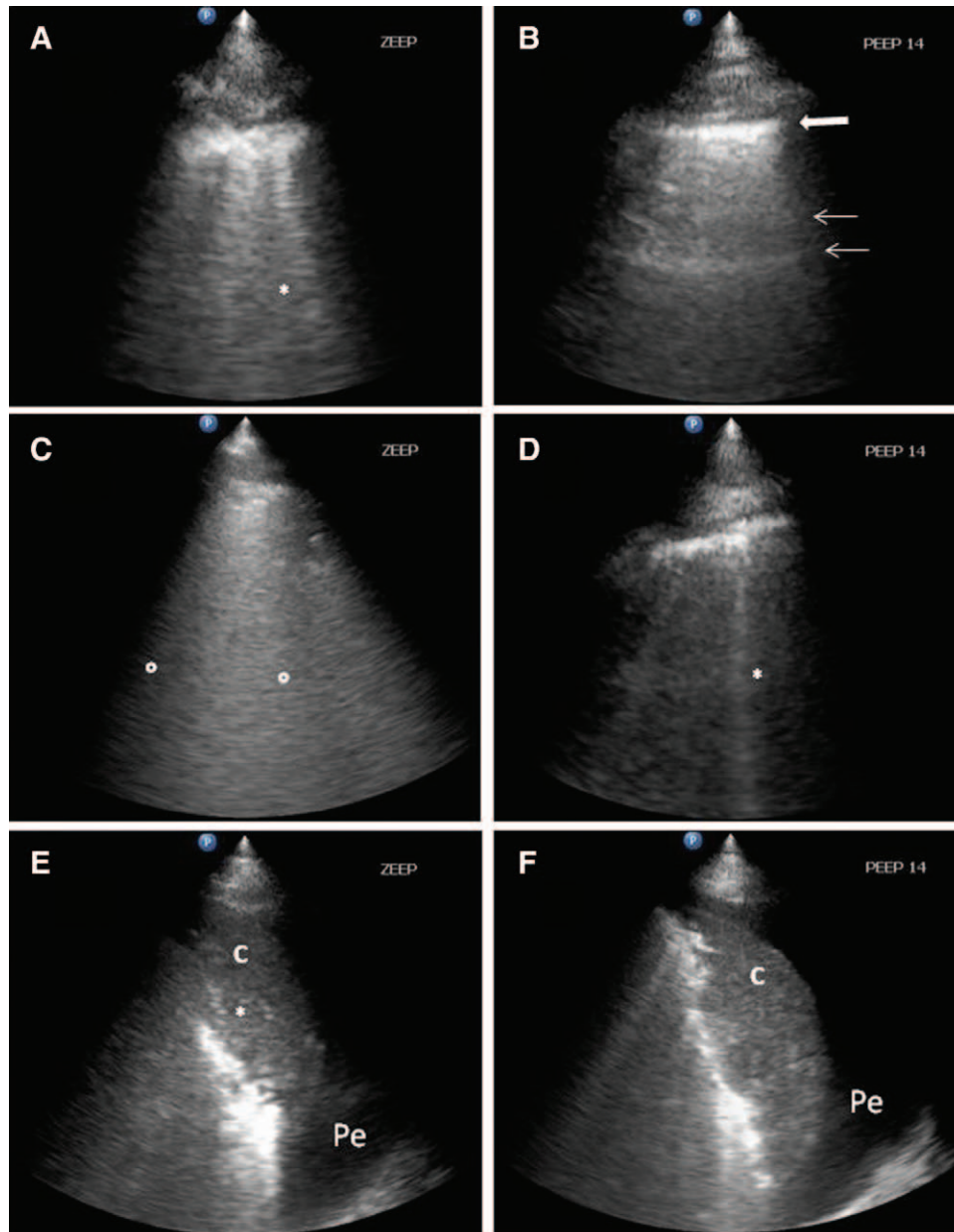
### **Lung Ultrasound to Quantify Lung Aeration Changes during the Spontaneous Breathing Trial**

Weaning from mechanical ventilation induces significant changes in lung aeration. Switching from positive pressure ventilation to spontaneous breathing is associated with changes in aeration depending on lung regions and the degree of lung healing: posterior and dependent lung regions may increase their aeration due to the active contraction of the diaphragm, whereas lateral and anterior nondependent lung regions may decrease their aeration. These opposite changes are easily highlighted by LUS during a spontaneous breathing trial.<sup>13</sup> In patients passing successfully a 1-h spontaneous breathing trial, ultrasound changes of lung aeration are predictive of extubation success or failure: in patients definitively weaned, overall lung aeration does not significantly change during the spontaneous breathing trial, whereas in patients with postextubation distress, lung aeration decreases during the spontaneous breathing trial.<sup>13</sup>

### **Lung Ultrasound to Diagnose and Monitor Ventilator-associated Pneumonia**

Ventilator-associated pneumonia (VAP) still remains a major complication of mechanical ventilation and a frequent cause of hypoxemia in critical patients. LUS, thanks to its bedside ready availability, has the potential to become a key tool in early VAP diagnosis.

LUS performs better than chest radiography in diagnosis of lung consolidation and interstitial–alveolar syndrome in critically ill patients.<sup>4</sup> In the emergency room, simple presence at LUS examination of consolidation with or without air bronchogram yields a sensitivity of 93% and a specificity of 98% for the diagnosis of community-acquired pneumonia.<sup>28</sup> But simple diagnosis of interstitial–alveolar syndrome or consolidation at LUS examination alone is not sufficient for diagnosis of VAP. Specific pathophysiology of VAP makes LUS particularly suitable for this diagnosis. Disseminated VAP-associated injury has a tendency to extend from the center to the periphery, reaching the surface and becoming therefore identifiable by LUS. When VAP progressively develops, the normal LUS pattern is gradually substituted by appearance of focal areas of interstitial syndrome (spaced B-lines, then becoming confluent B-lines), often associated with subpleural small consolidations and disseminated to anterior and lateral chest wall.<sup>14</sup> These subpleural consolidations could become

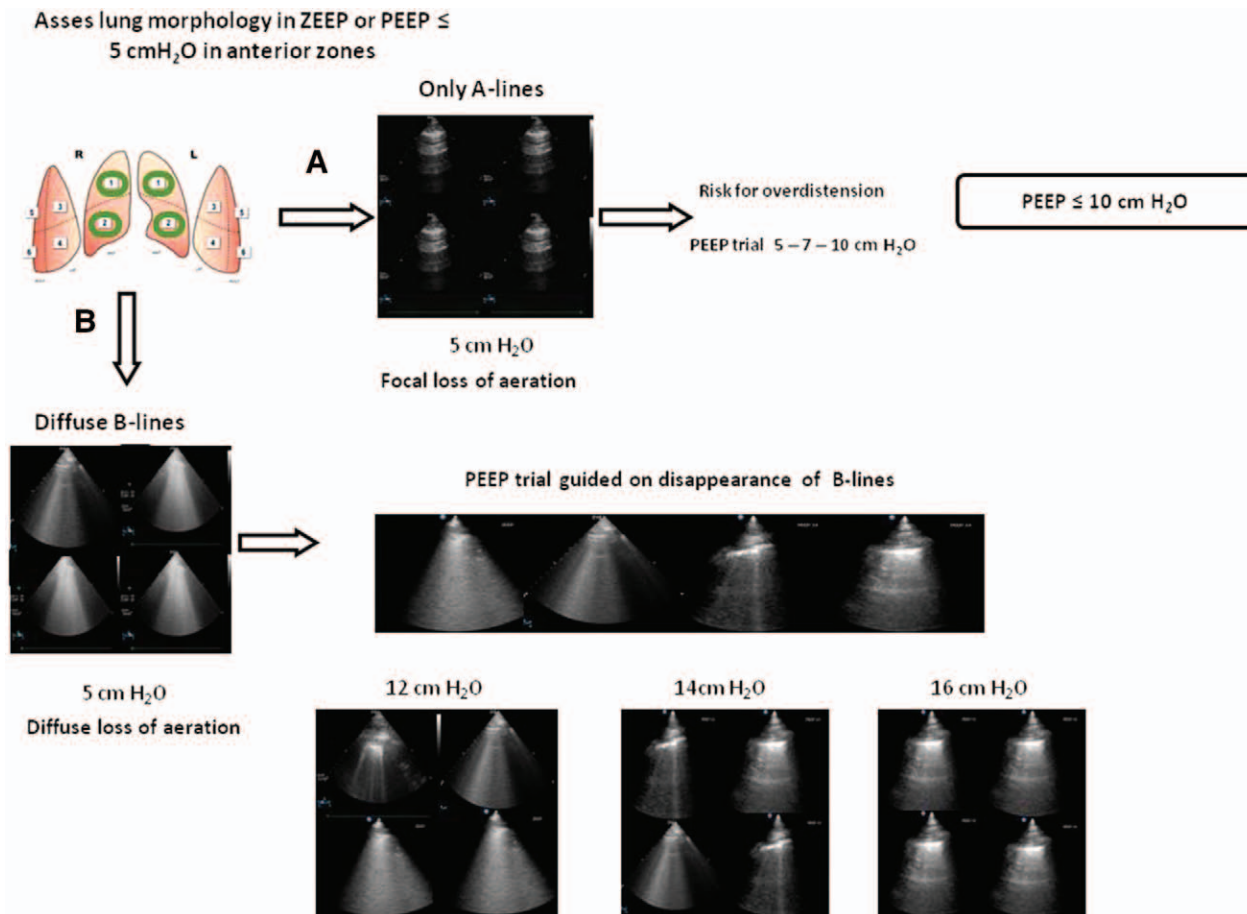


**Fig. 3.** Illustration of positive end-expiratory pressure (PEEP)-induced lung recruitment detected by ultrasound. In the same patient, transversal views of the upper anterior (A), lower lateral (C), and lower posterior (E) regions at zero end-expiratory pressure (ZEEP) (left) and at PEEP 14 cm H<sub>2</sub>O (right). (A) Left: interstitial syndrome with well-separated B-lines (\*). (B) After PEEP, the same lung region appears normally aerated. The pleural line (white arrow) and A-lines (thin arrows) can be seen. (C) Multiple coalescent B-lines (between °) are visible. (D) After PEEP, the same lung region appears more aerated with well-separated B-lines (\*). (E) Left: transversal view of consolidated lower lobe. Lung consolidation has tissue-like echotexture (c). Hyperechoic tubular or rounded images (\*) can be seen within the consolidation, corresponding to dynamic air bronchograms (air-filled bronchi). (F) Right: after PEEP 14 cm H<sub>2</sub>O, the left consolidation remained unchanged. Pe = pleural effusion.

progressively larger consolidations, up to lobar or hemilobar consolidations.<sup>14,29</sup> Despite existing evidence that LUS identifies VAP-specific signs (focal areas of interstitial syndrome, small subpleural consolidations, large consolidations, and fluid bronchogram; fig. 6) and monitors their evolution, no study has yet proven its accuracy in early VAP diagnosis.

Follow-up and monitoring of antibiotic therapy efficacy is the second major issue in VAP management. For VAP,

chest radiography is clearly not enough because it is poorly accurate for detecting changes in lung aeration after antimicrobial therapy.<sup>14</sup> LUS is an effective tool in the follow-up of VAP when compared with CT scan: antibiotic efficacy is associated with B-lines and subpleural consolidation disappearance, whereas antibiotic failure corresponds to new subpleural consolidation appearance or coalescing in lobar consolidation. In this study on VAP patients, lung re-aeration



**Fig. 4.** Lung ultrasound to titrate positive end-expiratory pressure (PEEP) in acute respiratory distress syndrome patients. The first step consists in evaluation of lung morphology of anterior areas at PEEP  $\leq$  5 cm H<sub>2</sub>O. (A) Presence of normally aerated patterns characterizes focal aeration loss. Level of PEEP  $>$  10 cm H<sub>2</sub>O exposes to overdistension of these zones. (B) Presence of well-separated or coalescent B-lines patterns characterizes diffuse loss of aeration. High level of PEEP (12 to 14 to 16 cm H<sub>2</sub>O) can be tested. At each increase in PEEP, responsiveness can be monitored by lung ultrasound examination of anterior zones. PEEP recruitment is characterized by disappearance of B-lines in these zones. ZEEP = zero end-expiratory pressure.

after 7 days of antimicrobial therapy was measured by CT scan and compared with LUS re-aeration score. A high correlation was found between LUS re-aeration score and CT re-aeration. In community-acquired pneumonia, monitoring mainly relies on sequential assessment of dimension and number of lobar consolidations.<sup>28</sup>

LUS could ideally represent the decision-making tool for antimicrobial therapy administration in the timeframe of the technical time required for bronchoalveolar lavage analysis. But specific data on LUS specificity and sensitivity for the diagnosis of VAP are still lacking and should be investigated.

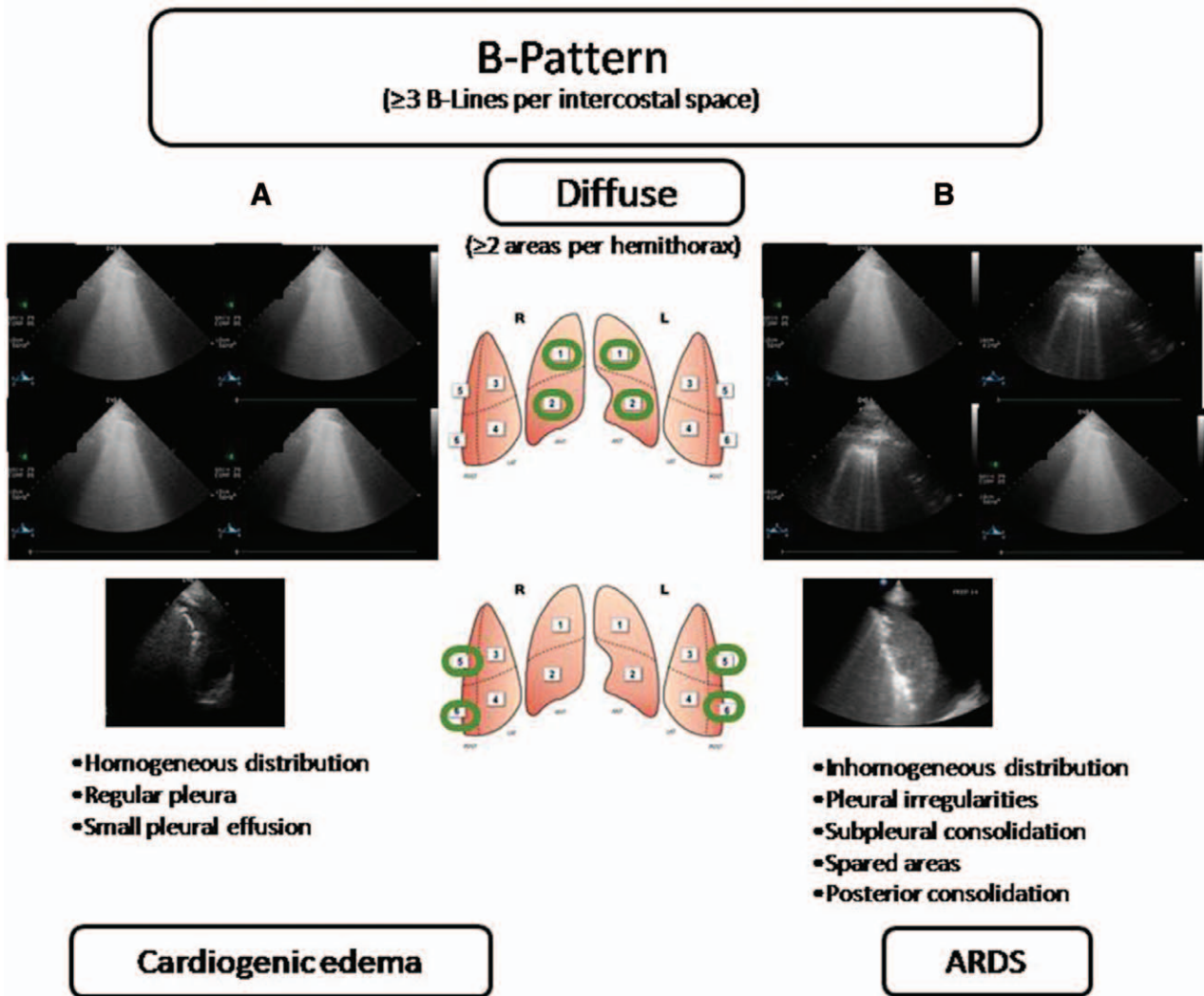
### Pneumothorax

Pneumothorax is an additional cause of increasing hypoxia in mechanically ventilated patients, mainly in stiff lung of ARDS patients. LUS can easily rule in or out pneumothorax, performing better than chest radiography.<sup>30,31</sup> In a supine patient, air collections move to nondependent regions, the echo-performer will start LUS examination from anterior fields. Presence of air

between the pleural layers compromises the visualization of underlying structures. If real images are visualized, such as consolidations or pleural effusions, pneumothorax can be immediately ruled out. Lung sliding and B-lines derived from the visceral pleura allow for easily ruling out pneumothorax (negative predictive value 100%).<sup>32</sup> If only static pleural line and A-lines are visualized, the suspicion of pneumothorax is high. Using M-mode passing through the pleural line, one can confirm the presence or absence of lung sliding: presence of lung sliding appears as a linear and grainy image (“seashore” pattern); absence of lung sliding and presence of static A-lines appears as a completely linear pattern (“stratosphere” pattern).

However, diagnosis of pneumothorax is not sure because areas of reduced sliding can be due to different pathologies such as pleural adhesions or emphysematous bullae. Diagnosis is confirmed if moving lateral and inferior, the lung point can be identified (positive predictive value 100%): it corresponds to the zone of dynamic transition from a pneumothorax to a normal pattern.<sup>33</sup> This zone is called the “lung point.” (See video of the lung point, Supplemental Digital





**Fig. 5.** Cardiogenic edema and acute respiratory distress syndrome (ARDS) patterns. (A) Cardiogenic edema with presence of multiple B-lines in all examined regions with regular pleural line. Small pleural effusion can be seen in dependent zones. (B) ARDS characterized by its heterogeneous pattern. Regions with multiple B-lines are associated with regions with A-lines (*sparing areas*). Subpleural consolidations can be seen associated to these B-lines. Presence of lung consolidations in dependent zones.

Content 7, <http://links.lww.com/ALN/B123>. To confirm the diagnosis of pneumothorax, examination should be extended to lateral regions of the chest wall to localize the point where the normal lung pattern [lung sliding at the left part of the screen] replaces the pneumothorax pattern [absent lung sliding and horizontal A-lines at the right part of the screen]. This point is called the “lung point.” In two dimensions, the sliding will appear from dependent regions in inspiration and disappear in expiration; in M-mode, sea-shore and stratosphere patterns will alternate. Identifying the lung point in multiple intercostal spaces, it is possible to map pneumothorax superficial extension and therefore its modification (tension pneumothorax).

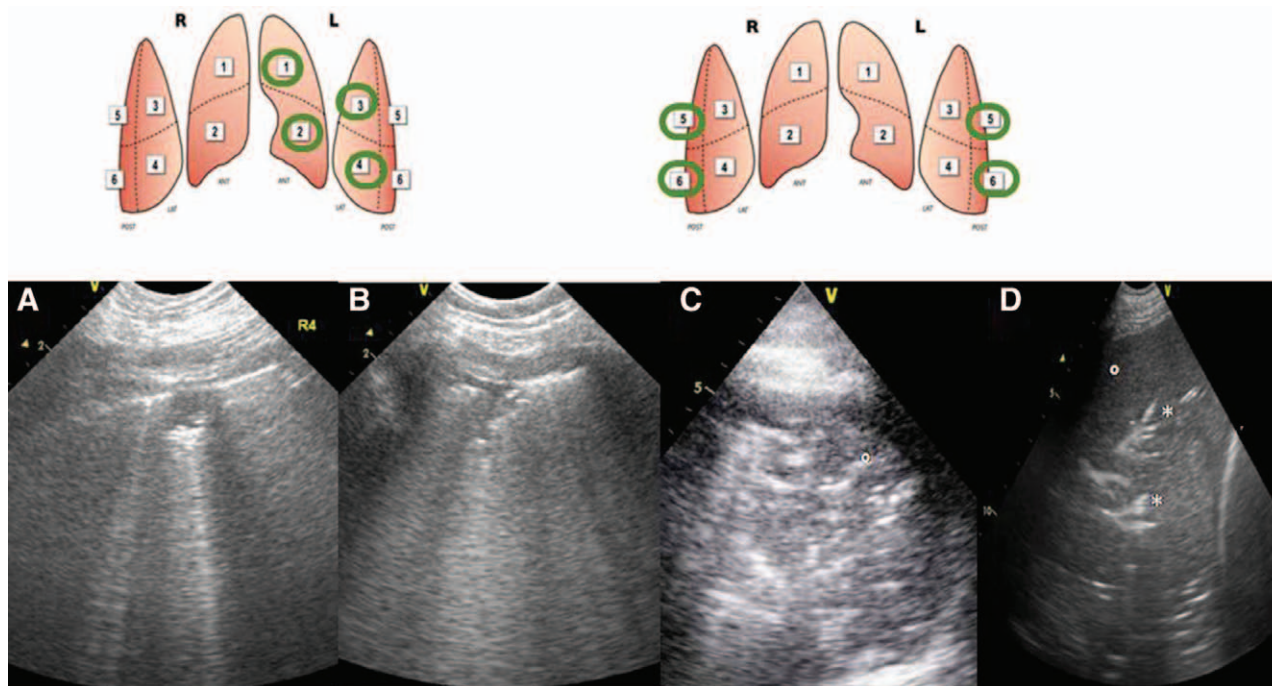
LUS has two main limitations in pneumothorax diagnosis. First, lung point will not be present if the lung is completely collapsed; in this case, the absence of ruling out signs associated to the clinical context should be suggestive enough.

Second, only the superficial extension can be mapped, not the thickness of air collection; therefore, LUS should be a guide to pneumothorax drainage only if the patient is unstable, otherwise the patient should undergo a more thorough examination (reference method, CT scan). An algorithm for the diagnosis of pneumothorax is given in figure 7.

### Research Perspectives

B-lines are associated with increased EVLW. Experimental studies are regularly undertaken to correlate B-lines to EVLW and to estimate it quantitatively. These studies relied on *ex vivo* animal lungs model. It was shown that B-lines appear in histologically normal *ex vivo* rabbit lungs that are deflated to a critical level of density.<sup>34</sup> In isolated bovine lung lobes, the amount of EVLW could be reliably estimated by LUS echointensity quantitatively determined by computer-assisted





**Fig. 6.** Lung ultrasound patterns in a patient with pneumonia. (A, B) Upper lobes: presence of subpleural consolidations associated to B-lines. (C) Transversal and (D) longitudinal view of lower lobe. Lung consolidation (°) appears as a tissue structure with hyperechoic tubular images (\*) corresponding to dynamic air bronchograms (D). Here, bronchograms are seen as arborescent and fluid-containing structures. They are called fluid bronchograms.

grayscale analysis.<sup>35</sup> In this model, different inflation pressures before and after instillation of known amounts of hypotonic saline were used to obtain different amounts of EVLW. EVLWs determined by LUS computer-assisted grayscale analysis were comparable with those obtainable by quantitative CT and superior to visual scoring of LUS.<sup>35</sup> Only one study in intensive care unit patients showed reliably the link between B-lines and pulmonary edema by using lung weight and density determined by quantitative CT scan.<sup>36</sup>

Evaluation of technology evolution in ultrasound, such as three-dimensional ultrasound and miniaturization, is also reported. Pocket-sized ultrasound devices have been recently developed and have a relative low cost. They are ideally suited for bedside use in emergency settings. Image quality should be lower than those of traditional device and limit ultrasound examination. However, focused ultrasound examination during patient bedside screening can provide accurate images allowing accurate diagnoses.<sup>37</sup> The semiquantitative evaluation of cardiac function and detection of cardiac abnormalities by focused ultrasound were already reported. Whether these devices will replace the conventional stethoscope for heart and lung examination remains to be determined.

### Limitations of Lung Ultrasound

LUS has operator-dependent limitations. LUS examination and correct interpretation of findings require formal training aimed at acquiring the necessary knowledge and skills. Training needs for diagnosis of elementary clinical questions

limited to easily identifiable signs of LUS were reported. Limited trainings of anesthesia residents allow them to “rule out” pneumothorax with a 5-min online training video.<sup>38</sup> Intensive care unit residents were able to diagnose pleural effusion after a few hours of a training course and hands-on training.<sup>39</sup>

LUS is also patient dependent. Obesity, subcutaneous emphysema, and the presence of large thoracic dressings preclude propagation of ultrasound beams from skin to lung.

Finally, LUS cannot detect lung overinflation resulting from an increase in intrathoracic pressures.

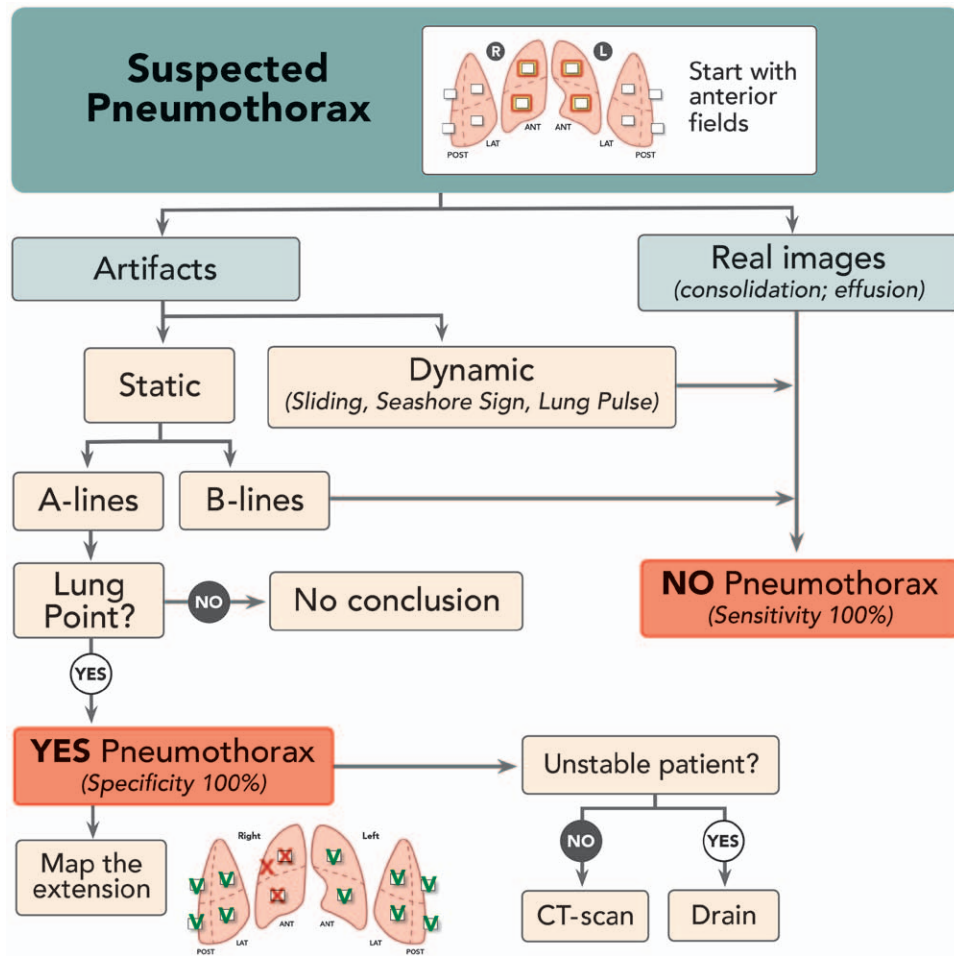
### Conclusion

The use of ultrasound has increased during the last 2 decades in critical care research and practice. LUS is an emerging technology particularly used for diagnosis of pneumothorax and pleural effusion. However, studies support that in the hands of relative experts, LUS provides accurate information on lung morphology with diagnostic and therapeutic relevance. It enables clinicians easy, rapid, and reliable evaluation of lung aeration and its variations at the bedside. LUS offers information that allows tailoring therapeutics and ventilator settings to each patient for better care.

### Acknowledgments

Support was provided solely from institutional and/or departmental sources.

### Competing Interests



**Fig. 7.** Algorithm used for the diagnosis of pneumothorax. ANT = anterior; CT = computed tomography; LAT = posterior; POST = posterior.

The authors declare no competing interests.

## Correspondence

Address correspondence to Dr. Bouhemad: Département d'Anesthésie-Réanimation, C.H.U. Dijon Hôpital du Bocage, BP 77908, 21079 Dijon Cedex, France. belaid\_bouhemad@hotmail.com. Information on purchasing reprints may be found at [www.anesthesiology.org](http://www.anesthesiology.org) or on the masthead page at the beginning of this issue. ANESTHESIOLOGY's articles are made freely accessible to all readers, for personal use only, 6 months from the cover date of the issue.

## References

- Rouby JJ, Constantin JM, Roberto De A Girardi C, Zhang M, Lu Q: Mechanical ventilation in patients with acute respiratory distress syndrome. *ANESTHESIOLOGY* 2004; 101:228–34
- Fiadjoe JE, Stricker P, Gurnaney H, Nishisaki A, Rabinowitz A, Gurwitz A, McCloskey JJ, Ganesh A: Ultrasound-guided tracheal intubation: A novel intubation technique. *ANESTHESIOLOGY* 2012; 117:1389–91
- Dubost C, Le Gouez A, Jouffroy V, Roger-Christoph S, Benhamou D, Mercier FJ, Geeraerts T: Optic nerve sheath diameter used as ultrasonographic assessment of the incidence of raised intracranial pressure in preeclampsia: A pilot study. *ANESTHESIOLOGY* 2012; 116:1066–71
- Lichtenstein D, Goldstein I, Mourgeon E, Cluzel P, Grenier P, Rouby JJ: Comparative diagnostic performances of auscultation, chest radiography, and lung ultrasonography in acute respiratory distress syndrome. *ANESTHESIOLOGY* 2004; 100:9–15
- Manno E, Navarra M, Faccio L, Motevallian M, Bertolaccini L, Mfochivè A, Pesce M, Evangelista A: Deep impact of ultrasound in the intensive care unit: The "ICU-sound" protocol. *ANESTHESIOLOGY* 2012; 117:801–9
- Pelosi P, Corradi F: Ultrasonography in the intensive care unit: Looking at the world through colored glasses. *ANESTHESIOLOGY* 2012; 117:696–8
- Zieleskiewicz L, Contargyris C, Brun C, Touret M, Vellin A, Antonini F, Muller L, Bretelle F, Martin C, Leone M: Lung ultrasound predicts interstitial syndrome and hemodynamic profile in parturients with severe preeclampsia. *ANESTHESIOLOGY* 2014; 120:906–14
- Mayo PH, Beaulieu Y, Doelken P, Feller-Kopman D, Harrod C, Kaplan A, Oropello J, Vieillard-Baron A, Axler O, Lichtenstein D, Maury E, Slama M, Vignon P: American College of Chest Physicians/La Société de Réanimation de Langue Française statement on competence in critical care ultrasonography. *Chest* 2009; 135:1050–60
- Bouhemad B, Zhang M, Lu Q, Rouby JJ: Clinical review: Bedside lung ultrasound in critical care practice. *Crit Care* 2007; 11:205
- Volpicelli G, Elbarbary M, Blaivas M, Lichtenstein DA, Mathis G, Kirkpatrick AW, Melniker L, Gargani L, Noble VE,

- Via G, Dean A, Tsung JW, Soldati G, Copetti R, Bouhemad B, Reissig A, Agricola E, Rouby JJ, Arbelot C, Liteplo A, Sargsyan A, Silva F, Hoppmann R, Breikreutz R, Seibel A, Neri L, Storti E, Petrovic T; International Liaison Committee on Lung Ultrasound (ILC-LUS) for International Consensus Conference on Lung Ultrasound (ICC-LUS): International evidence-based recommendations for point-of-care lung ultrasound. *Intensive Care Med* 2012; 38:577-91
11. Lichtenstein DA, Lascols N, Mezière G, Gepner A: Ultrasound diagnosis of alveolar consolidation in the critically ill. *Intensive Care Med* 2004; 30:276-81
  12. Bouhemad B, Brisson H, Le-Guen M, Arbelot C, Lu Q, Rouby JJ: Bedside ultrasound assessment of positive end-expiratory pressure-induced lung recruitment. *Am J Respir Crit Care Med* 2011; 183:341-7
  13. Soummer A, Perbet S, Brisson H, Arbelot C, Constantin JM, Lu Q, Rouby JJ; Lung Ultrasound Study Group: Ultrasound assessment of lung aeration loss during a successful weaning trial predicts postextubation distress\*. *Crit Care Med* 2012; 40:2064-72
  14. Bouhemad B, Liu ZH, Arbelot C, Zhang M, Ferarri F, Le-Guen M, Girard M, Lu Q, Rouby JJ: Ultrasound assessment of antibiotic-induced pulmonary re-aeration in ventilator-associated pneumonia. *Crit Care Med* 2010; 38:84-92
  15. Tsubo T, Sakai I, Suzuki A, Okawa H, Ishihara H, Matsuki A: Density detection in dependent left lung region using transesophageal echocardiography. *ANESTHESIOLOGY* 2001; 94:793-8
  16. Tsubo T, Yatsu Y, Suzuki A, Iwakawa T, Okawa H, Ishihara H, Matsuki A: Daily changes of the area of density in the dependent lung region—Evaluation using transesophageal echocardiography. *Intensive Care Med* 2001; 27:1881-6
  17. Tsubo T, Yatsu Y, Tanabe T, Okawa H, Ishihara H, Matsuki A: Evaluation of density area in dorsal lung region during prone position using transesophageal echocardiography. *Crit Care Med* 2004; 32:83-7
  18. Stefanidis K, Dimopoulos S, Tripodaki ES, Vitzilaios K, Politis P, Piperopoulos P, Nanas S: Lung sonography and recruitment in patients with early acute respiratory distress syndrome: A pilot study. *Crit Care* 2011; 15:R185
  19. Gattinoni L, Caironi P, Cressoni M, Chiumello D, Ranieri VM, Quintel M, Russo S, Patroniti N, Cornejo R, Bugeo G: Lung recruitment in patients with the acute respiratory distress syndrome. *N Engl J Med* 2006; 354:1775-86
  20. Vieira SR, Puybasset L, Richecoeur J, Lu Q, Cluzel P, Gusman PB, Coriat P, Rouby JJ: A lung computed tomographic assessment of positive end-expiratory pressure-induced lung overdistension. *Am J Respir Crit Care Med* 1998; 158(5 Pt 1):1571-7
  21. Copetti R, Soldati G, Copetti P: Chest sonography: A useful tool to differentiate acute cardiogenic pulmonary edema from acute respiratory distress syndrome. *Cardiovasc Ultrasound* 2008; 6:16
  22. Copetti R, Cattarossi L, Macagno F, Violino M, Furlan R: Lung ultrasound in respiratory distress syndrome: A useful tool for early diagnosis. *Neonatology* 2008; 94:52-9
  23. Agricola E, Bove T, Oppizzi M, Marino G, Zangrillo A, Margonato A, Picano E: "Ultrasound comet-tail images": A marker of pulmonary edema: A comparative study with wedge pressure and extravascular lung water. *Chest* 2005; 127:1690-5
  24. Agricola E, Picano E, Oppizzi M, Pisani M, Meris A, Fragasso G, Margonato A: Assessment of stress-induced pulmonary interstitial edema by chest ultrasound during exercise echocardiography and its correlation with left ventricular function. *J Am Soc Echocardiogr* 2006; 19:457-63
  25. Lichtenstein DA, Mezière GA, Lagoueyte JF, Biderman P, Goldstein I, Gepner A: A-lines and B-lines: Lung ultrasound as a bedside tool for predicting pulmonary artery occlusion pressure in the critically ill. *Chest* 2009; 136:1014-20
  26. Noble VE, Murray AF, Capp R, Sylvia-Reardon MH, Steele DJ, Liteplo A: Ultrasound assessment for extravascular lung water in patients undergoing hemodialysis. Time course for resolution. *Chest* 2009; 135:1433-9
  27. Gheorghide M, Follath F, Ponikowski P, Barsuk JH, Blair JE, Cleland JG, Dickstein K, Drazner MH, Fonarow GC, Jaarsma T, Jondeau G, Sendon JL, Mebazaa A, Metra M, Nieminen M, Pang PS, Seferovic P, Stevenson LW, van Veldhuisen DJ, Zannad F, Anker SD, Rhodes A, McMurray JJ, Filippatos G; European Society of Cardiology; European Society of Intensive Care Medicine: Assessing and grading congestion in acute heart failure: A scientific statement from the acute heart failure committee of the heart failure association of the European Society of Cardiology and endorsed by the European Society of Intensive Care Medicine. *Eur J Heart Fail* 2010; 12:423-33
  28. Reissig A, Copetti R, Mathis G, Mempel C, Schuler A, Zechner P, Aliberti S, Neumann R, Kroegel C, Hoyer H: Lung ultrasound in the diagnosis and follow-up of community-acquired pneumonia: A prospective, multicenter, diagnostic accuracy study. *Chest* 2012; 142:965-72
  29. Via G, Lichtenstein D, Mojoli F, Rodi G, Neri L, Storti E, Klersy C, Iotti G, Braschi A: Whole lung lavage: A unique model for ultrasound assessment of lung aeration changes. *Intensive Care Med* 2010; 36:999-1007
  30. Agricola E, Arbelot C, Blaivas M, Bouhemad B, Copetti R, Dean A, Dulchavsky S, Elbarbary M, Gargani L, Hoppmann R, Kirkpatrick AW, Lichtenstein D, Liteplo A, Mathis G, Melniker L, Neri L, Noble VE, Petrovic T, Reissig A, Rouby JJ, Seibel A, Soldati G, Storti E, Tsung JW, Via G, Volpicelli G: Ultrasound performs better than radiographs. *Thorax* 2011; 66:828-9; author reply 829
  31. Blaivas M, Lyon M, Duggal S: A prospective comparison of supine chest radiography and bedside ultrasound for the diagnosis of traumatic pneumothorax. *Acad Emerg Med* 2005; 12:844-9
  32. Lichtenstein D, Mezière G, Biderman P, Gepner A: The comet-tail artifact: An ultrasound sign ruling out pneumothorax. *Intensive Care Med* 1999; 25:383-8
  33. Lichtenstein DA, Mezière G, Lascols N, Biderman P, Courret JP, Gepner A, Goldstein I, Tenoudji-Cohen M: Ultrasound diagnosis of occult pneumothorax. *Crit Care Med* 2005; 33:1231-8
  34. Soldati G, Inchingolo R, Smargiassi A, Sher S, Nenna R, Inchingolo CD, Valente S: *Ex vivo* lung sonography: Morphologic-ultrasound relationship. *Ultrasound Med Biol* 2012; 38:1169-79
  35. Corradi F, Ball L, Brusasco C, Riccio AM, Baroffio M, Bovio G, Pelosi P, Brusasco V: Assessment of extravascular lung water by quantitative ultrasound and CT in isolated bovine lung. *Respir Physiol Neurobiol* 2013; 187:244-9
  36. Baldi G, Gargani L, Abramo A, D'Errico L, Caramella D, Picano E, Giunta F, Forfori F: Lung water assessment by lung ultrasonography in intensive care: A pilot study. *Intensive Care Med* 2013; 39:74-84
  37. Biais M, Carrié C, Delaunay F, Morel N, Revel P, Janvier G: Evaluation of a new pocket echoscopic device for focused cardiac ultrasonography in an emergency setting. *Crit Care* 2012; 16:R82
  38. Krishnan S, Kuhl T, Ahmed W, Togashi K, Ueda K: Efficacy of an online education program for ultrasound diagnosis of pneumothorax. *ANESTHESIOLOGY* 2013; 118:715-21
  39. Vignon P, Dugard A, Abraham J, Belcour D, Gondran G, Pepino F, Marin B, François B, Gastinne H: Focused training for goal-oriented hand-held echocardiography performed by noncardiologist residents in the intensive care unit. *Intensive Care Med* 2007; 33:1795-9